

QUT Digital Repository:
<http://eprints.qut.edu.au/>



Markey, Bryan and Wan, Charles and Hanger, Jon and Phillips, Che and Timms, Peter (2007) Use of quantitative real-time PCR to monitor the shedding and treatment of chlamydiae in the koala (*Phascolarctos cinereus*) . *Veterinary Microbiology* 120(3-4):pp. 334-342.

© Copyright 2007 Elsevier

**Use of Quantitative Real-Time PCR to Monitor the Shedding and Treatment of Chlamydiae in the Koala
(*Phascolarctos cinereus*)**

Bryan Markey^{1*}, Charles Wan², Jon Hanger³, Che Phillips³ and Peter Timms².

¹School of Agriculture, Food Science and Veterinary Medicine, University College Dublin, Ireland

²School of Life Sciences, Queensland University of Technology, Brisbane, Australia

³Australian Wildlife Hospital, Beerwah, Queensland, Australia

Running Title: Quantitative monitoring of chlamydial shedding in the koala

Correspondent contact details:

School of Agriculture, Food Science and Veterinary Medicine, University College Dublin, Belfield, Dublin 4, Ireland.

Tel: +353-1-7166183. Fax: +353-1-7166185. E-mail: Bryan.Markey@UCD.ie

Abstract

The aim of this study was to monitor chlamydial shedding patterns in clinically affected koalas before, during and following treatment using quantitative real-time PCR. Swab samples were obtained from 14 koalas presented for treatment at the Australian Wildlife Hospital. Four of these animals were followed over a period of eight to nine weeks. Primers were designed based on the consensus signature sequence of the 16S rRNA chlamydial gene. Additional primers were designed based on the sequence of the koala beta actin gene and used to normalise chlamydial values when comparing results from different swab samples. Chlamydial 16S rRNA gene copy number was highest in swab samples from clinically affected sites. Daily injections of chloramphenicol resulted in a marked and rapid reduction in the numbers of chlamydiae being shed from all sites. In general chlamydial copy number was no longer detectable by the end of the second week of treatment. No evidence of relapse of infection was detected at two weeks after the cessation of treatment. In contrast, topical chloramphenicol treatment of the eyes required a longer treatment period and had little effect on the shedding of chlamydiae from other sites of the body. Further studies are required to confirm the efficacy of a shorter treatment period.

Keywords: chlamydiae, koala, real time PCR, shedding, treatment

Introduction

In the koala (*Phascolarctos cinereus*), chlamydiae have been associated with keratoconjunctivitis (Cockram and Jackson, 1974; Hemsley and Canfield, 1997) as well as genital (Brown and Grice, 1984; Higgins et al., 2005; McColl et al., 1984) and urinary tract infection (Brown and Grice, 1984; Brown et al., 1987; Hemsley and Canfield, 1997; Higgins et al., 2005). Both *Chlamydomphila pecorum* and *Cp. pneumoniae* infect the koala (Girjes et al., 1988; Glassick et al., 1996). Chlamydial infection is considered to be widespread in most koala populations (Martin, 1985; Mitchell et al., 1988; Weigler et al., 1988; White and Timms, 1994) with published prevalence rates varying depending on the population studied and the method of detection used. Using isolation in tissue culture, White and Timms (1994) reported a prevalence rate of 39 to 61% in south eastern Queensland. The same study estimated the prevalence of clinical disease to be 15 to 20%. The polymerase chain reaction (PCR) assay has been well established as a sensitive and reliable method of detection of chlamydiae in the koala (Devereaux et al., 2003; Jackson et al., 1999). Jackson et al. (1999) used DNA-based procedures for the detection and speciation of chlamydiae in two free-ranging koala populations in south eastern Queensland. In one population the level of chlamydial infection was 85% with clinical disease apparent in 17% of animals. The prevalence of infection in the second population was only 10% despite the presence of the same genotype of *Cp. pecorum* in the two populations. Out of a total of 24 koalas infected with *Cp. pecorum*, five had evidence of clinical disease while none out of seven infected with *Cp. pneumoniae* showed any signs of disease. Using DNA sequence analysis of the variable domain IV of the major outer membrane protein (MOMP) gene, Jackson et al. (1997) separated 15 koala *Cp. pecorum* isolates into five genetically distinct groups. In addition, sequencing of part of the 16S rRNA gene has indicated that infections also occur with a genetically diverse array of chlamydiae distinct from any of the established chlamydial species (Devereaux et al., 2003).

Chlamydial infections in the koala have been estimated as ranging from low to high grade based on the intensity of staining following amplification and DNA probe hybridization (Jackson et al., 1999), but actual levels of infection in the koala have not been quantified accurately to date. Despite the large number of free-ranging koalas presented to wildlife facilities for treatment of chlamydiosis, particularly in south east Queensland (G. Gipp, personal communication; Environmental Protection Agency, 2005), there are no detailed reports of treatment regimes or efficacy in the scientific literature. Nottidge (2002) reported an absence of clinical signs in two free-ranging koalas seven months after release back into the wild following treatment of severe bilateral keratoconjunctivitis. The treatment regime included systemic therapy with chloramphenicol as well as topical therapy with ophthalmic preparations containing chloramphenicol and corticosteroids. However, that study did not seek to determine shedding of chlamydiae following

treatment. The aims of the current study were to utilise real-time PCR to quantify the shedding of chlamydiae in animals presenting with a range of clinical backgrounds at a wildlife hospital and to determine the effect of treatment on shedding over a period of several weeks.

Materials and Methods

Animals

Swab samples were obtained from five clinically normal koalas at Lone Pine Koala Sanctuary, Brisbane. Swab samples were also obtained from 14 free-ranging koalas presented for treatment at the Australian Wildlife Hospital, Beerwah, Australia (Table 1). An indication of the age of the animals was obtained by assessing the amount of wear on the premolar and molar teeth of an individual (White and Kunst, 1990). The animals were generally presented to the wildlife hospital by concerned members of the public or by wildlife rehabilitation volunteers. Reasons for presentation were bad condition, disease and trauma (i.e. vehicle collision and dog injury). After a detailed clinical examination, animals could be divided into three subgroups based on different clinical presentations:

- Group 1 Ophthalmic disease, unilateral or bilateral kerato-conjunctivitis characterized, most commonly, by copious mucopurulent discharge, and varying degrees of conjunctival proliferation (granulation), keratitis and palpebral scarring (koalas 1, 2, 3, 12 and 14)
- Group 2 Urine staining of the rump (“dirty tail” or “wet bottom”) as a result of chronic cystitis (koalas 4, 5, 6, 7, 8, 9, 10, 11)
- Group 3 Ophthalmic disease *and* urine staining of the rump (koala 13)

Ophthalmic and urinary tract disease were generally quite obvious by external clinical signs. In contrast, reproductive tract disease in female koalas was most commonly diagnosed after anaesthesia by palpation or ultrasound detection of reproductive tract cysts or by the presence of a severe, bilateral open pyometron.

Treatment

Koalas 1, 2, 4, 7, 8, and 13 were considered on clinical grounds to be suitable for treatment and rehabilitation. Koalas 3, 5, 6, 9, 10, 11, 12, 14 had lesions sufficient to justify euthanasia on humane grounds. With the exception of one case (koala 1) in which a single injection of chloramphenicol was administered followed by topical eye treatments only as described below, koalas with clinical signs of chlamydiosis were treated with subcutaneous injections of chloramphenicol 150mg/ml (Chloramphenicol 150, Delvet Pty. Ltd., New South Wales, Australia) at a dose rate of

60mg/kg once each day for 45 days. Koalas with keratoconjunctivitis were treated by bathing of eyes to remove exudate, then twice daily topical application of an eye ointment containing chloramphenicol 10mg/g and hydrocortisone acetate 5mg/g (Chloroptone Eye Ointment, Delvet Pty. Ltd., New South Wales, Australia) and twice daily application of eye drops containing dexamethasone 1 mg/ml (Maxidex 0.1%, Alcon Laboratories, Australia). Koalas with cystitis were treated with regular rump washing and a variety of antibiotics for secondary infections as indicated by culture and sensitivity testing.

Sampling procedures

Samples were collected from four of the animals (koalas 1, 7, 8 and 13) during the course of their treatment initially every three days and then weekly and finally fortnightly over a period of 8 to 9 weeks. The final sample was obtained two weeks following the cessation of treatment. In the case of a further two animals, samples were obtained up till day 6 (koala 2) and day 9 (koala 4) post admission respectively. One koala (koala 9) was sampled on two occasions before her euthanasia for humane reasons. The remaining seven koalas were sampled only once and were then euthanized on humane grounds at the time of clinical examination because of the severity of disease and consequently poor prognosis.

Animals were anaesthetized each time sampling occurred by intramuscular injection of alfaxalone 10mg/ml (Alfaxan CD RTU®, Jurox New Zealand) at a dose rate of 3mg/kg. Anaesthesia was maintained by inhalation with a mixture of isoflurane and oxygen administered to effect by mask or endotracheal tube. Up to nine swabs per sampling event were collected from different sites using sterile aluminium-shafted fine cotton-tipped swabs (Copan, Italy). All or some of the following sites were swabbed: left eye exudate, right eye exudate, left conjunctiva, right conjunctiva, left and right nasal cavity (pooled), oropharynx, urogenital sinus (females), penile urethra (males), rectum and urine sediment. Swabs of urine sediment were obtained by centrifugation of up to 1.5 ml of urine, removal of supernatant and swabbing of the resultant pellet. In some cases, urine was collected by cystocentesis, in others by manual expression of the bladder. In some cases, particularly if cystitis was present, urine was unable to be obtained because the bladder was empty.

Isolation of DNA and real time PCR

The swab samples were stored at -70°C until the DNA was extracted as described by Devereaux et al. (2003). Briefly, one ml of sucrose phosphate glutamine (SPG) was added to each swab and vortexed vigorously. Then 0.5 ml of the cell suspension was centrifuged at 13,000 x g for 30 min and the pellet resuspended in 40 µl of SPG before heating at 95°C for 10 mins. The PCR mixture consisted of 1 µl of DNA template, 10 µl of 2X Sybr Green PCR Master Mix (Applied

Biosystems, Foster City, California), 250 nM concentrations (each) of the forward and reverse primers made up to a final volume of 20 μ l with PCR-grade water.

The 16S rRNA real time primers were designed using the consensus signature sequence published by Everett et al. (1999). OLIGO Primer Analysis software (Molecular Biology Insights Inc., Cascade, Colorado) was used to assist in the selection of all primer sequences used in this study. The primer pair 16S rt F (5'-GCTTGTTGGTGGGGTAA-3') and 16S rt R (5'-CAGTGTGGCGGTCAAT-3') targeted a 72 base pair region of the 16S rRNA gene.

Standards of known concentration of 10^2 , 10^4 , 10^6 and 10^8 copy numbers of the target 16S rRNA gene sequence were prepared as follows. DNA extracted from a known positive *Cp. pecorum* koala sample was amplified by PCR using the 16S rRNA gene real time primers. The PCR product was electrophoresed in a 2% agarose/TBE (45 mM Tris-borate and 1 mM EDTA, pH 8.0) gel, stained with ethidium bromide ($0.5 \mu\text{g ml}^{-1}$) and visualized with a UV transilluminator ($\lambda = 302 \text{ nm}$). The band was cut out of the gel and the DNA purified using the High Pure PCR Product Purification Kit (Roche, Applied Science, Germany) according to the manufacturer's instructions. The concentration of DNA in the purified preparations was determined by spectrophotometric measurement of absorbance at 260 and 280 nm wavelengths. The number of molecules of product was calculated using Avogadro's formula.

All reactions were carried out on an Applied Biosystems 7000 SDS real-time PCR machine (Applied Biosystems, Foster City, California). Following an initial incubation of 95°C for 10 min to activate the DNA polymerase, 40 cycles of 10 sec at 95°C and 30 sec at 60°C were carried out followed by a final dissociation stage. DNA samples from a known *Cp. pecorum* infected koala and from a known *Cp. pneumoniae* infected koala were used as positive controls while water was used as a negative control. All the samples were tested in triplicate.

On account of the varying amounts of clinical material obtained by this method of sampling and to facilitate comparisons between the results obtained from different swab samples, samples were also tested in triplicate for the presence of the koala beta-actin gene (separate wells on the same 96 well plate being used to test for the presence of chlamydial 16S rDNA). DNA samples from a cloned portion of the koala beta-actin gene and water were used as positive and negative controls, respectively. The copy number was normalised by dividing the 16S rRNA gene copy number by the beta-actin gene copy number. The beta-actin primers were designed from the koala beta-actin gene, accession number DQO58212. The primer pair K beta-actin F (5'-TGCATCTAGCTCCTCTCTGG-3') and K beta-actin R (5'-GCATCGGAACCTCTCGT-3') targeted a 82 base pair region of the koala beta-actin gene. Standards of known concentration of 10^2 , 10^4 , 10^6 and 10^8 copy numbers of the target beta-actin gene sequences were prepared as follows. DNA extracted from a nasal swab sample from a koala was amplified by PCR using the beta-actin primers and purified

using the Qiaex II Gel Extraction Kit (Qiagen Inc., Valencia, California) according to the manufacturer's instructions. The purified product was cloned using the pGEM-T vector (Promega Corp., Madison, Wisconsin) in *Escherichia coli* JM109 cells according to the manufacturer's instructions.

Samples were considered positive for the presence of chlamydiae when a 16S rRNA gene copy number greater than one was present in the sample and the dissociation curve profile matched that of the positive controls. In order to compare chlamydial copy number from one swab with another, the 16S rRNA gene copy number was divided by the corresponding beta-actin gene copy number to produce a normalised 16S rRNA gene copy number.

16S rRNA gene sequencing

Ten positive samples including both ocular and urogenital samples from eight different koalas (koalas 2, 4, 7, 8, 10, 12, 13 and 14) were amplified using the 16S rRNA gene 'signature sequence' primers described by Everett et al. (1999) and sequenced by the dideoxynucleotide method (Sanger and Coulson, 1977). A 294 bp consensus sequence was generated from nucleotide sequence alignment of the 10 sequences obtained using CLUSTAL W (version 1.82; <http://www.ebi.ac.uk>; 21).

Results

Clinically normal animals

One of the five was found PCR-positive for chlamydiae, but only in the urogenital tract swab, where 24 copies were detected.

Clinically diseased and treated animals

The results of the treated animals (Figure 1) have been grouped on the basis of their primary clinical presentation into one of three categories: ophthalmic disease, urogenital tract disease, and both ophthalmic and urogenital tract disease. With the exception of koala 12, female koalas with reproductive tract disease also had chronic cystitis, as evidenced by marked urine staining of the fur of the rump.

Koalas presenting with ophthalmic disease only

Chlamydial copy number was much higher in swabs from clinically affected eyes than in swabs from other sites. Some shedding was detected in the nasal swabs from two animals but the chlamydial copy number was ≤ 20 . In contrast the oro-pharyngeal swabs were negative. Chlamydial DNA was present in the urogenital and urine sediment swabs of animals presenting because of ophthalmic disease, but generally at much lower levels (ranging from 0 to 715 copy

number) than was detected in the swabs from the animals with urogenital tract disease. Koala 2 was found to be PCR-positive for chlamydiae in the rectal swab.

Koalas presenting with urogenital disease only:

The urogenital and urine sediment swab samples from the animals with signs of urogenital tract disease contained very high chlamydial copy number with one urogenital swab sample containing 8.64×10^7 per swab, the highest amount recorded during the study. The rectal swabs were PCR-positive in some of the animals.

Koalas presenting with both ophthalmic and urogenital tract disease

Chlamydial copy number was high in both ocular and urogenital swabs in animals presenting with both conjunctivitis and urogenital tract disease. One eye swab contained 1.02×10^7 copy number per swab, the highest level observed in any eye swab over the course of the study. The chlamydial copy number was relatively high in the rectal swabs from three of the four animals in this group.

Normalised 16S rRNA gene copy number

The concurrent beta-actin gene assay confirmed the presence of host cells on swabs. For 91% of samples (86 out of 95 samples tested) koala host cells were evident in the test sample, however, in the other nine samples tested the absence of any beta-actin copy number suggested little or no clinical material had been obtained during the swabbing process. In addition, the successful amplification of the beta-actin gene demonstrated in several cases that 16S rRNA gene-negative samples were negative due to absence of chlamydial DNA rather than due to the presence of inhibitors to the reaction. Normalisation of the 16S rRNA copy number tended to result in significantly increased values for urinary sediment swabs compared with results from other sites. This effect occurred whether the samples were taken from animals with ocular infections or from animals with urogenital tract infection (results not shown).

Response to treatment

In most of the treated animals the shedding of chlamydiae was no longer detectable by the end of the second week of treatment. Occasional increases in chlamydial copy number occurred subsequently but these were generally of a low level and of short duration (Figure 2). Chlamydial shedding by koala 13 was dramatically reduced by day 13 of antibiotic therapy at all sites and remained negative for the rest of the observation period except for a temporary, small rise in copy number in the nasal sample at day 20. In contrast, in the case of koala 1 (Figure 3) chlamydial copy number remained at a significant level in the urogenital swab samples and also increased for a period in the right eye and rectal samples. This is probably due to the fact that this animal received only one injection of chloramphenicol and was principally treated topically.

16S rRNA gene sequencing

All ten chlamydial isolates sequenced in this study were the same genotype. BLAST analysis of the GenBank database gave highest similarity with *Cp. pecorum* 16S rRNA gene sequences and a perfect match with 5 of 11 *Cp. pecorum* 16S rRNA gene sequences compared with in the database.

Discussion

Chlamydial infection is considered to be the most important cause of disease in the koala (Brown and Grice, 1984; Brown et al., 1987) with infection being widespread in many koala populations (Jackson et al., 1999; White and Timms, 1994). This is the first study to apply real-time PCR to the determination of the shedding patterns of chlamydiae in naturally infected wild koalas and to the assessment of the efficacy of antibiotic therapy on chlamydial infection in those animals.

Chlamydial 16S rRNA gene copy number reflected clinical presentation in most cases, being high in the swab samples from clinically affected sites. This was particularly well illustrated in the case of unilateral eye infections. In general, higher levels of chlamydial DNA were detected in urogenital and urinary sediment swab samples than in ocular swab samples. It is possible that this is simply a reflection of the numbers of host cells available for infection. If an arbitrary figure of 300 chlamydial particles is assigned to a typical chlamydial inclusion and if each beta-actin gene detected represents a single host cell, it was estimated that a peak infection rate of 1:5 host cells occurred in the urinary tract, 1:30 host cells in the lower urogenital tract and 1:300 host cells in the eye.

Chlamydial copy number in urogenital swab samples was frequently mirrored by rectal swab samples from the same animal. It is likely that the close anatomical relationship between the two orifices, commonly termed the cloaca, may have led to cross contamination of the samples. The nasal and oro-pharyngeal samples were often negative, even in animals with ocular disease. It was surprising that infection did not extend down the nasolachrymal duct to the nasal chamber. A number of the oro-pharyngeal swabs were also negative for the beta-actin gene. This could have been due to a failure to collect host cells.

Detection of the beta-actin gene yielded a number of benefits by confirming the presence of clinical material on the swabs as well as confirming the absence of inhibitors to DNA amplification. Normalisation of chlamydial copy number values has previously been used by Dean et al. (2005) to permit comparisons between serial ocular swabs from cats experimentally infected with *Cp. felis*. In the present study, the normalisation of copy number values produced markedly raised values for the urinary sediment samples relative to those for all the other sites. As a result, the

normalisation of values did not provide any additional value in the interpretation of results when comparing the results obtained for different sample sites at a particular time point.

Successful treatment of koalas with chlamydial infection has traditionally been difficult due to factors such as the severity and chronicity of disease, presence of secondary infections and apparent immunodeficiency syndrome (Hanger, 1999). In the present study, daily treatment with parenterally administered chloramphenicol resulted in a rapid reduction in the numbers of chlamydiae being shed from all sites. The continued absence of chlamydial DNA in all samples obtained two weeks following the cessation of treatment, with the exception of koala Jada, strongly suggests that the treatment regime used was effective in clearing the chlamydial infection fully. Among the advantages of the treatment regime used in this study is a single daily treatment eliminating the need to handle animals more than once a day. Based on the results presented in this study it is likely that the duration of treatment could be reduced to 3 weeks without a loss of efficacy. This contrasts with the situation in cats infected with *Cp. felis* where recent studies suggest that treatment should be continued for at least four weeks (Dean et al., 2005). However, a previous study in cats indicated that a much shorter treatment duration is effective (Sykes et al., 1999). Further studies are required to assess the risk of relapse in koalas treated for a shorter period of time.

The finding that all of the positive-PCR samples sequenced were *Cp. pecorum* was not unexpected given the significantly higher prevalence rate of *Cp. pecorum* infection compared to *Cp. pneumoniae* in some free-range koala populations (Jackson et al., 1999). In addition, the study by Jackson *et al.* (1999) found that *Cp. pecorum* infection was present in all koalas with clinical disease examined suggesting that *Cp. pecorum* may be the more pathogenic of the two species. It is possible that mixed chlamydial infections may have been missed in this study as the primers used were not species specific and the PCR-products were not cloned prior to sequencing.

Conclusion

In conclusion, this is the first study to apply real-time 16S rRNA PCR to the study of chlamydial infection in the koala. Chlamydiae are shed in large numbers from the urogenital tract and the conjunctivae of clinically affected koalas. Use of a second primer set to detect the koala beta-actin gene served as a useful external control, confirming the presence of adequate clinical material and the absence of inhibitors to the amplification reaction. Antibiotic therapy rapidly reduced the level of infection with parenteral treatment effectively eliminating the infection from all sites after approximately two weeks of treatment in most cases. Topical ocular treatment had little effect on chlamydial shedding from sites other

than the eyes. Further studies of this nature are required to assess other therapeutic regimes in koalas and to confirm the efficacy of a shorter treatment duration.

Acknowledgements

The authors wish to gratefully acknowledge the financial support received from the Queensland University of Technology SARC grant scheme and the invaluable assistance given by the clinical staff at the Australian Wildlife Hospital and animal handlers at Lone Pine Koala Sanctuary.

References

- Brown, A.S. and Grice R.G., 1984. Isolation of *Chlamydia psittaci* from koalas (*Phascolarctos cinereus*). Aust. Vet. J. **61**, 413.
- Brown, A.S., Girjes A.A., Lavin M.F., Timms P. and Woolcock J.B., 1987. Chlamydial disease in koalas. Aust. Vet. J. **64**, 346-349.
- Cockram, F.A. and Jackson A.R.B., 1974. Isolation of a *Chlamydia* from cases of keratoconjunctivitis in koalas. Aust. Vet. J. **50**, 82.
- Dean, R., Harley R., Helps C., Caney S., and Gruffydd-Jones T., 2005. Use of quantitative real-time PCR to monitor the response of *Chlamydomphila felis* infection to doxycycline treatment. J. Clin. Microbiol. **43**, 1858-1864.
- Devereaux, L.N., Polkinghorne A., Meijer A., and Timms P., 2003. Molecular evidence for novel chlamydial infections in the koala (*Phascolarctos cinereus*). System. Appl. Microbiol. **26**, 245-253.
- Environmental Protection Agency, Queensland Government. 2005. [Online]
<http://www.epa.qld.gov.au/register/p01469ak.pdf> Koala Conservation Plan Report.
- Everett, K.D., Bush R.M., and Andersen A.A., 1999. Emended description of the order *Chlamydiales*, proposal of *Parachlamydiaceae* fam. nov. and *Simkaniaceae* fam. nov., each containing one monotypic genus and five new species, and standards for the identification of organisms. Int. J. Syst. Bacteriol. **49**, 415-440.
- Girjes, A.A., Hugall A., Timms P., and Lavin M.F., 1988. Two distinct forms of *Chlamydia psittaci* associated with disease and infertility in *Phascolarctos cinereus* (koala). Infect. Immun. **56**, 1897-1900.
- Glassick, T.V., Giffard P., and Timms P., 1996. Outer membrane protein 2 gene sequence indicates that two species, *Chlamydia pecorum* and *Chlamydia pneumoniae* cause infection in koalas. System. Appl. Microbiol. **19**, 457-464.

- Hanger, J.J. 1999. An investigation of the role of retroviruses in leukaemia and related diseases in koalas. PhD Thesis. University of Queensland, Brisbane.
- Hemsley S. and Canfield P.J., 1997. Histopathological and immunohistochemical investigation of naturally occurring chlamydial conjunctivitis and urogenital inflammation in koalas (*Phascolarctos cinereus*). J. Comp. Path. **116**, 273-290.
- Higgins, D.P., Hemsley S., and Canfield P.J., 2005. Immuno-histochemical demonstration of the role of *Chlamydiaceae* in renal, uterine and salpingeal disease of the koala, and demonstration of chlamydiaceae in novel sites. J. Comp. Path. **133**, 164-174.
- Jackson, M., Giffard P., and Timms P.. 1997. Outer membrane protein A gene sequencing demonstrates the polyphyletic nature of koala *Chlamydia pecorum* isolates. System. Appl. Microbiol. **20**, 187-200.
- Jackson, M., White N., Giffard P., and Timms P.. 1999. Epizootiology of *Chlamydia* infections in two free-ranging koala populations. Vet. Microbiol. **65**, 255-264.
- Martin, R.W., 1985. Overbrowsing and decline of a population of the koala, *Phascolarctos cinereus*, in Victoria. III. Population dynamics. Aust. Wildl. Res. **16**, 377-386.
- Mitchell, P.J., Bilney R., and Martin R.W., 1988. Population structure and reproductive status of koalas on Raymond Island, Victoria. Aust. Wildl. Res. **15**, 511-514.
- McColl, K.A., Martin R.W., Gleeson L.J., Handasyde K.A., and Lee A.K., 1984. Chlamydia infection and infertility in the female koala (*Phascolarctos cinereus*). Vet. Rec. **115**, 655.
- Nottidge, B.J. 2002. Monitoring the health and dispersal of rehabilitated and translocated koalas (*Phascolarctos cinereus*) at two release sites on the Gold Coast. Honours Thesis, University of Queensland, Brisbane.
- Sanger, F.N.S. and Coulson A.R., 1977. DNA sequencing with chain-terminating inhibitors. Proceed. Natl. Acad. Sci. **7**, 5463-5467.
- Sykes, J.E., Studdert V.P., and Browning G.F., 1999. Comparison of the polymerase chain reaction and culture for the detection of *Chlamydia psittaci* in untreated and doxycycline-treated experimentally infected cats. J. Vet. Intern. Med. **13**, 146-152.
- Thompson J.D., Higgins D.G., and Gibson T.J., 1994. CLUSTAL W: improving the sensitivity of progressive multiple sequence alignment through sequence weighting, position-specific gap penalties and weight matrix choice. Nucleic Acids Res. **22**, 4673-4680.

- Weigler, B.J., Girjes A.A., White N.A., Kunst N.D., Carrick F.N. and Lavin M.F., 1988. Aspects of the epidemiology of *Chlamydia psittaci* infection in a population of koalas (*Phascolarctos cinereus*) in southern Queensland, Australia. *J. Wildl. Dis.* **24**, 282-291.
- White, N.A. and Kunst N.D., 1990. Aspects of the ecology of the koala in southeastern Queensland. pp. 109-116. *In* A.K. Lee, K.A. Handasyde and G.D. Sanson (ed), *Biology of the Koala*. Surrey Beatty and Sons, Sydney.
- White, N.A. and Timms P., 1994. *Chlamydia psittaci* in a koala (*Phascolarctos cinereus*) population in south-east Queensland. *Wildl. Res.* **21**, 41-47.

Table 1 Details of history and clinical findings in 14 diseased koalas treated at the Australian Wildlife Hospital.

Figure 1 Mean chlamydial 16S rRNA gene copy number in koalas with ophthalmic disease (Group 1), koalas with urogenital tract disease (Group 2) and koalas with both ophthalmic and urogenital tract disease (Group 3) (log scale).

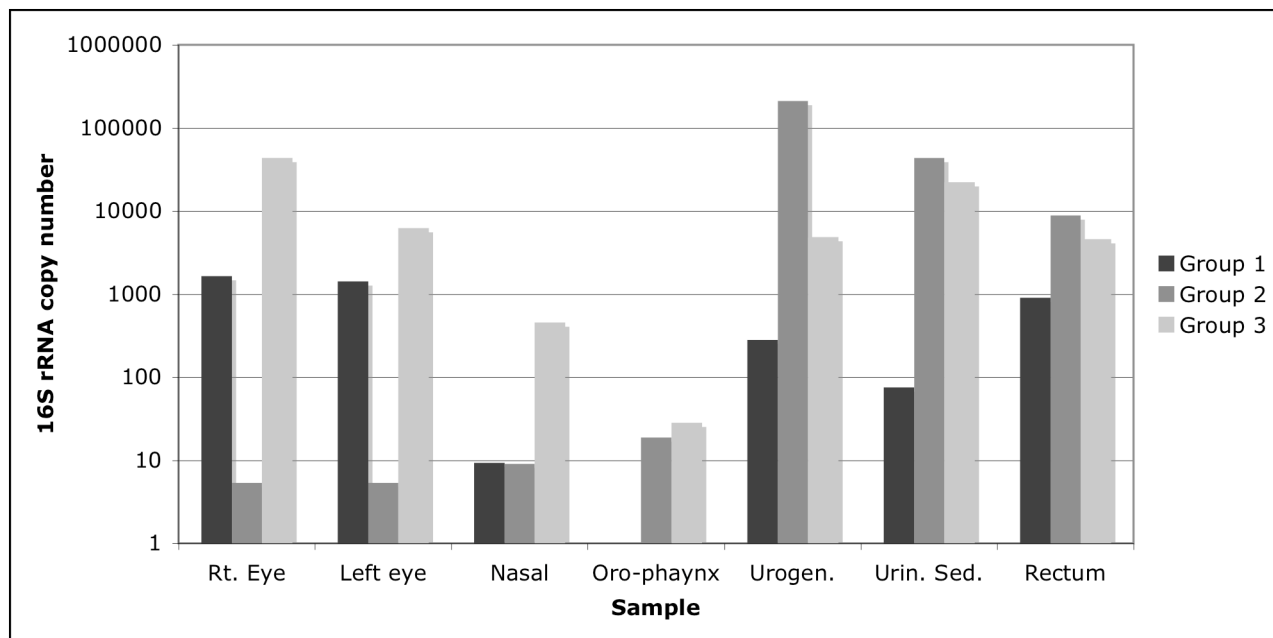
Rt. = right; Urogen. = urogenital tract; Urin. Sed. = urinary sediment.

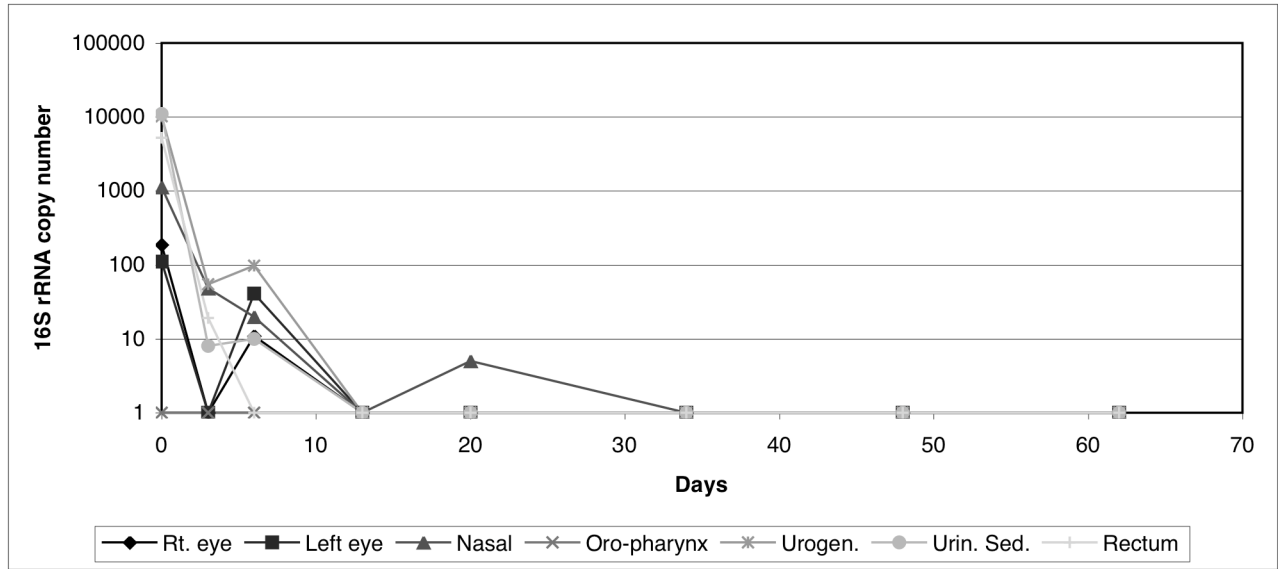
Figure 2 Serial shedding pattern of chlamydiae by koala 13 during full course of treatment (log scale).

Rt. = right; Urogen. = urogenital tract; Urin. Sed. = urinary sediment.

Figure 3 Serial shedding pattern of chlamydiae by koala 1 during full course of treatment (log scale).

Rt. = right; Urogen. = urogenital tract; Urin. Sed. = urinary sediment.





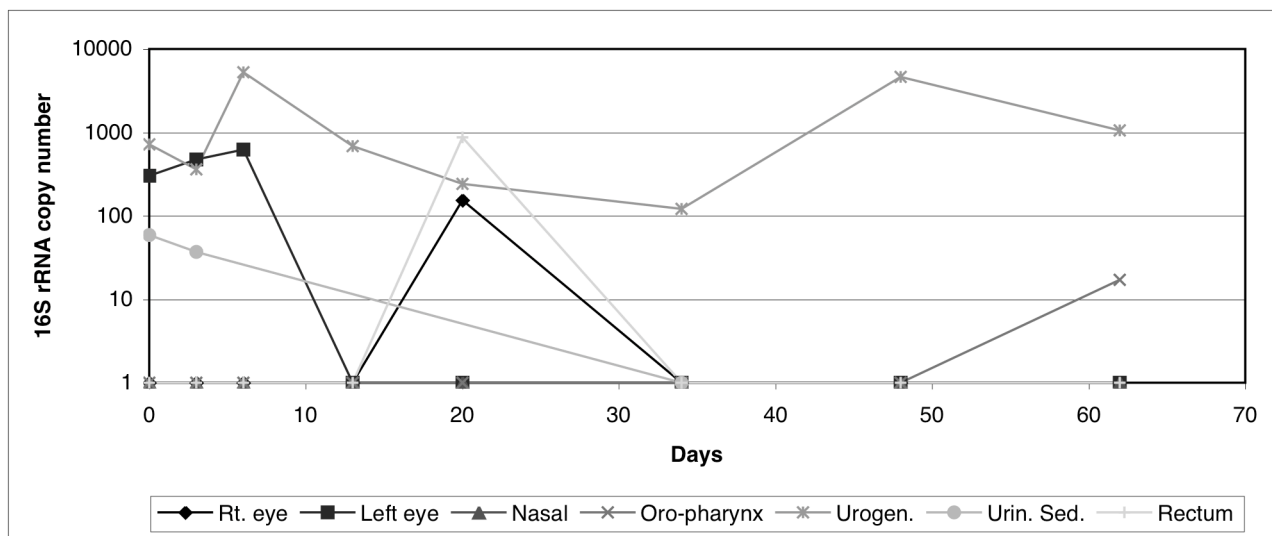


Table 1 Details of history and clinical findings in 14 diseased koalas treated at the Australian Wildlife Hospital.

Animal	Sex/Age	History/Clinical signs
1	Female 4 yr	Dog attack, no puncture wounds detected. Mild unilateral conjunctivitis (left eye), single injection of chloramphenicol followed by topical treatment only. Good body coat, no pouch young, no abnormalities on ultrasound. Admitted for treatment.
2	Male 5 yr	Bilateral kerato-conjunctivitis. Admitted for treatment.
3	Male 3 yr	Proliferative kerato-conjunctivitis of right eye. Poor body condition. Severe aplastic anaemia, thrombocytopenia, leukopenia (myelodysplastic syndrome, blast cells predominate in bone marrow). Euthanasia.
4	Female 3 yr	Dirty tail. Severe chronic cystitis (large numbers of cocci in urine sediment). No ocular disease and no palpable or ultrasonic evidence of reproductive tract disease. Admitted for treatment.
5	Female 4 yr	Marked dirty tail but cloaca okay. Slight discoloration of fur around left eye but no exudate. Large reproductive tract cyst palpable. Euthanasia.
6	Male 3 yr	Severe dirty tail and bilateral markedly dilated ureters. Euthanasia.
7	Male 2 yr	Severe dirty tail. Marked thickening of bladder wall. Admitted for treatment.
8	Female 3 yr	Poor body condition. Severe dirty tail, chronic cystitis. Marked thickening and spasm of bladder wall. Mild dilatation of right ureter but no detectable reproductive pathology. Admitted for treatment.
9	Female 2 yr	Poor body condition, dirty tail. Chronic cystitis and severe reproductive tract disease (pyometron). Euthanasia.
10	Female 8 yr	Chronic dirty tail. Poor body condition. Large, multiple reproductive tract cysts. Euthanasia.
11	Female 8 to 12 yr	Severe, chronic dirty tail. Dilated right ureter and poor body condition. No reproductive tract cysts palpable. Very poor body condition. Euthanasia.
12	Female 4 yr	Severe bilateral keratoconjunctivitis. Reproductive tract cysts detected. No evidence of cystitis. Euthanasia.
13	Male 5 yr	Hit by a car, but mild injuries. Bilateral kerato-conjunctivitis and dirty tail. Admitted for treatment.
14	Male 5 yr	Poor body condition, thoracic scoliosis, cystitis, bilateral severe kerato-conjunctivitis, mild stomatitis/pharyngitis and periodontal disease. Mild cystitis (no dirty tail but evidence in urine sediment of neutrophils and bacteria). Euthanasia.