

Cerebellar grey-matter deficits, cannabis use and first-episode schizophrenia in adolescents and young adults

Martin Cohen^{1,2,3*}, Paul E. Rasser^{1,2,3*}, Greg Peck², Vaughan J. Carr^{1,4}, Philip B. Ward⁴, Paul M. Thompson⁵, Patrick Johnston⁶, Amanda Baker^{1,2,3} and Ulrich Schall^{1,2,3}

¹ Schizophrenia Research Institute, Sydney, Australia

² Priority Centre for Brain & Mental Health Research, The University of Newcastle, Australia

³ Hunter Medical Research Institute, Newcastle, Australia

⁴ School of Psychiatry, University of New South Wales, Sydney, Australia

⁵ Laboratory of Neuro Imaging, University of California Los Angeles, CA, USA

⁶ Department of Psychology, University of York, UK

Abstract

Epidemiological data link adolescent cannabis use to psychosis and schizophrenia, but its contribution to schizophrenia neuropathology remains controversial. First-episode schizophrenia (FES) patients show regional cerebral grey- and white-matter changes as well as a distinct pattern of regional grey-matter loss in the vermis of the cerebellum. The cerebellum possesses a high density of cannabinoid type 1 receptors involved in the neuronal diversification of the developing brain. Cannabis abuse may interfere with this process during adolescent brain maturation leading to 'schizophrenia-like' cerebellar pathology. Magnetic resonance imaging and cortical pattern matching techniques were used to investigate cerebellar grey and white matter in FES patients with and without a history of cannabis use and non-psychiatric cannabis users. In the latter group we found lifetime dose-dependent regional reduction of grey matter in the right cerebellar lobules and a tendency for more profound grey-matter reduction in lobule III with younger age at onset of cannabis use. The overall regional grey-matter differences in cannabis users were within the normal variability of grey-matter distribution. By contrast, FES subjects had lower total cerebellar grey-matter: total cerebellar volume ratio and marked grey-matter loss in the vermis, pedunculi, flocculi and lobules compared to pair-wise matched healthy control subjects. This pattern and degree of grey-matter loss did not differ from age-matched FES subjects with comorbid cannabis use. Our findings indicate small dose-dependent effects of juvenile cannabis use on cerebellar neuropathology but no evidence of an additional effect of cannabis use on FES cerebellar grey-matter pathology.

Received 8 December 2010; Reviewed 10 January 2011; Revised 31 March 2011; Accepted 4 April 2011;

First published online 4 May 2011

Key words: Cerebellum, magnetic resonance imaging, parametric mapping, psychosis, THC.

Introduction

Cannabis is the most commonly used illicit drug, abused by approximately 4% of the adult population worldwide (United Nations Office on Drugs and Crime, 2008). Particularly high rates are recorded for North America and Oceania. Approximately 40%

of the North American population aged ≥ 12 yr (Substance Abuse and Mental Health Services Administration, 2009) and 34% of the Australian population aged ≥ 14 yr (Australian Institute of Health and Welfare, 2008) had a reported lifetime use of cannabis. The European Union recorded lower rates at 22% for the 15–64 yr age group (Vicente *et al.* 2008). Of particular concern is the increasing trend for using hydroponically grown cannabis with significantly higher tetrahydrocannabinol (THC) content at younger ages (see review by Copeland & Swift, 2009).

Meta-analyses by Moore and colleagues (2007) show that there is an increased risk of psychosis

Address for correspondence: Mr P. E. Rasser, Priority Centre for Brain & Mental Health Research, The University of Newcastle, Mater Hospital, McAuley Centre, Waratah NSW 2298, Australia.
Tel.: +61 2 4033 5691

Email: Paul.Rasser@newcastle.edu.au

* These authors contributed equally as joint first authors.

(i.e. beyond the immediate impact of intoxication) in individuals who had ever used cannabis and a greater risk in people who have used cannabis more frequently. Although the authors concluded that an association with mood and affective disorders was less clear, the observation of increased risk of psychosis raises health concerns for the mental wellbeing of young regular users of cannabis.

Cannabis is a plant derivative of *Cannabis sativa*, *C. indica*, and *C. ruderalis* which differ in their respective THC and cannabidiol content. THC is the main psychoactive compound and acts on the CB1 cannabinoid receptor in the nervous system. In the human brain, the highest density of CB1 receptors is found in the midbrain (i.e. substantia nigra, red nucleus, central grey, and superior colliculus), followed by the basal ganglia (i.e. globus pallidus) and the molecular layer of the cerebellum. Lower densities are found in layer I of the primary and secondary visual cortex (Glass *et al.* 1997).

In the adult brain, endocannabinoids (e.g. anandamide and 2-arachnidonoylglycerol) mediate retrograde synaptic signalling, thereby controlling synaptic plasticity. CB1 receptors play an integral role in synapto-, neuro- and morphogenesis as well as neuronal migration and specification during brain development (Harkany *et al.* 2008). Postnatal brain maturation is largely defined by myelination and synaptic pruning. These processes result in grey-matter thinning and a white-matter volume increase (e.g. Gogtay & Thompson, 2010).

Of particular interest are the neurodevelopmental processes of adolescence and early adulthood when schizophrenia emerges and cannabis abuse is most prevalent. The role of the endocannabinoid system in this phase of brain maturation remains unclear, but the continued expression of CB1 receptors in brain regions that change during adolescence suggests an ongoing role, e.g. in synapse formation (Harkany *et al.* 2008).

There is clear evidence for substantial structural brain changes in first-episode schizophrenia (FES), including some evidence suggesting that these changes already emerge in the prodromal phase of illness (e.g. Borgwardt *et al.* 2007; Lappin *et al.* 2007; Takahashi *et al.* 2009; Witthaus *et al.* 2009). Rais and colleagues further reported that FES patients who have used cannabis show a more pronounced brain volume reduction over a 5-yr period than patients with schizophrenia who did not use cannabis (Rais *et al.* 2008). While these authors did not report cerebellum data, cerebellar atrophy has been detected in individuals followed longitudinally from the prodromal phase of

the illness (Borgwardt *et al.* 2008; Pantelis *et al.* 2003). Progression of vermal atrophy in childhood-onset schizophrenia patients has not been confirmed by repeated magnetic resonance imaging (MRI) (Keller *et al.* 2003). Together, these findings support the notion of cerebellar neuropathology in schizophrenia that is already present in the emerging phase of illness. We investigated whether a history of juvenile cannabis consumption in the prodromal phase of illness was also associated with more pronounced cerebellar neuropathology in FES as reported for the cerebrum (Rais *et al.* 2008).

Cannabis-induced brain changes in otherwise healthy individuals are comparatively less prominent (for review see Martín-Santos *et al.* 2010). Reported cannabis-induced brain changes range from altered gyrification in young users, consistent with neurodevelopmental abnormalities (Mata *et al.* 2010), to volumetric reductions of amygdala and hippocampus in an exposure-dependent fashion (Yucel *et al.* 2008). In the latter study, sub-threshold positive symptoms were also correlated with left-hemispheric hippocampal volume reduction and cumulative lifetime exposure to cannabis. Compared to studies of structural brain changes, functional brain-imaging studies are more common. These predominantly show reduced prefrontal blood flow in cannabis users compared to non-users (for review see Martín-Santos *et al.* 2010). However, there are very few studies specifically investigating effects of juvenile cannabis use on the cerebellum. For instance, Medina *et al.* (2010) reported larger vermal volumes in recently abstinent cannabis users, along with impaired executive functions, which is in contrast to the findings reported for the cerebrum showing smaller regional volumes with cannabis use in a dose-dependent fashion (e.g. Yucel *et al.* 2008).

Here we report on the neurodevelopmental effects of juvenile cannabis use on the CB1-rich grey matter of the cerebellum (Glass *et al.* 1997) in a group of young people with heavy cannabis abuse during adolescence. We hypothesized that cerebellar grey-matter reduction would be related to: (1) age at onset of cannabis use (i.e. greater reduction when use starts at a younger age); (2) duration of cannabis use (i.e. more grey-matter reduction with longer use); and (3) the total amount of accumulated lifetime dose (i.e. dose-dependent reduction of grey matter).

We also examined the effect of cannabis use on cerebellar pathology in young people diagnosed with FES (e.g. Okugawa *et al.* 2007; Thomann *et al.* 2009; Whitford *et al.* 2006). We hypothesized that (4) FES cannabis users would show greater regional grey-matter reduction in the cerebellum compared to a

Table 1. Demographic, handedness, age at psychosis onset, cannabis, alcohol and tobacco use data [standard deviations (s.d.) given in parentheses] for healthy control subjects, cannabis-using subjects, first-episode schizophrenia (FES) subjects, and cannabis-using FES subjects

	Control subjects	Cannabis-using subjects	FES	Cannabis-using FES	<i>p</i>
Male/female	15/4	15/2	12/1	4/2	0.64 ^a
Age, yr (s.d.)	21.5 (2.3)	22.7 (2.4)	20.7 (3.6)	21.8 (1.9)	0.24 ^b
Handedness (R/L)	19/0	17/0	13/0	6/0	–
Age at first psychotic episode, yr (s.d.)	–	–	17.5 (2.5)	17.4 (2.2)	0.96 ^b
Age, yr, at onset of THC use (s.d.)	–	15.1 (2.4)	–	15.5 (2.3)	0.74 ^b
Years of THC use (s.d.)	–	7.6 (2.6)	–	6.3 (2.3)	0.30 ^b
Estimated total lifetime THC doses (s.d.)	–	22 700 (16 400)	–	17 900 (19 000)	0.56 ^b
Estimated alcohol consumption, grams/day (s.d.)	11.2 (14.5)	24.1 (24.0)	18.0 (6.0)	29.7 (27.2)	0.09 ^b
Daily tobacco consumption (Y/N)	7/12	13/4	5/8	3/6	0.14 ^a

^a χ^2 test (Yates-corrected).

^b One-way ANOVA.

group of non-using FES, and that (5) cannabis use contributes to and overlaps with the cerebellar grey-matter reduction pattern found in non-using FES. The latter hypothesis reflects the notion of a promoting effect of juvenile cannabis use on cerebellar pathology as, for instance, Bangalore *et al.* (2008) reported as decreased grey-matter density in the CB1 receptor-rich region of right posterior cingulate cortex when employing a voxel-based morphometric analysis and comparing cannabis-using with non-using FES patients.

Methods

Ethics approval for this study was granted by the human research ethics committees of the Universities of Newcastle and New South Wales, Hunter New England Health, and South Eastern Sydney Area Health. Participants gave written informed consent.

Subjects

Nineteen healthy non-drug-using volunteers, 17 young cannabis users, 13 non-using and six cannabis-using FES outpatients were recruited through community advertisement. FES patients had a history of <5 yr since their first psychotic episode and <2 yr since meeting DSM-IV criteria for schizophrenia (First *et al.* 1997). All four participant groups were closely matched for age, gender and handedness as well as for cannabis-use history (for the cannabis-using subjects) and duration of illness (for the FES subjects; Table 1). FES participants were in remission after no more than one hospital admission and were maintained on

atypical antipsychotic monotherapy (i.e. risperidone, olanzapine, aripiprazole, quetiapine) when recruited into the study.

The Opiate Treatment Index (Darke *et al.* 1991) was used to assess illicit and licensed drug use and to estimate the quantity/frequency of cannabis use expressed as individual consumption events and referred to as 'doses' (Darke *et al.* 1991; Table 1). All participants were right-handed (Edinburgh Handedness Scale; Oldfield, 1971). Exclusion criteria for all participants included non-cannabis forms of substance abuse or dependence, other than caffeine or nicotine according to DSM-IV criteria. As a result, the groups did not differ on any substance use patterns other than cannabis (Table 1). Other exclusion criteria included: a history of significant head injury, relevant neurological (e.g. epilepsy) or medical (e.g. endocrine) conditions, ferromagnetic implants, claustrophobia or other anxiety disorders, failure to complete at least 3 yr of secondary school, or National Adult Reading Test (Nelson & Willison, 1991) IQ estimates of <70.

Magnetic resonance data acquisition and processing

MRI data were acquired using a Siemens Magnetom Vision 1.5 T MRI scanner (John Hunter Hospital, Newcastle, Australia). High-resolution structural brain MR data were collected from each subject with approximate dimensions of 164 × 256 × 256 with each voxel being 1 × 1 × 1 mm. We used a 3D MPRAGE (magnetization prepared gradient echo) protocol with repetition time (TR) = 9.7 ms, echo time (TE) = 4 ms, and flip angle = 12°.

Pre-processing of the subject's MRI scan followed a protocol (Rasser *et al.* 2010) involving transformation to ICBM space (Mazziotta *et al.* 2001), radio-frequency bias correction (Sled *et al.* 1998), manual delineation of the cerebellum (blind to diagnosis) followed by the extraction of a surface-based model of the cerebellar cortex (MacDonald *et al.* 1994). Using the surface model and all three triaxial sections of the subject's MRI, five cerebellar fissures (intra-culminate, primary, superior posterior, horizontal, secondary) were identified and traced onto their cerebellar model (Fig. 1a). A cortical pattern-matching technique (Rasser *et al.* 2010; Thompson *et al.* 2004) was then employed to deform each subject's cerebellar model to a geometrically averaged target set of fissures.

Using a dilated version of their native space cerebellar mask, a secondary correction for radio-frequency bias (intensity inhomogeneity) was applied to the subject's MRI to improve the homogeneity of intensities within each tissue class. Each subject's cerebellum was then isolated using their cerebellar mask, followed by intensity normalization, and total cerebellar volume was calculated.

Cerebellar grey- and white-matter tissues were classified using a thresholding procedure (Atkins & Mackiewicz, 1998). This procedure divided the tissue classes based on a constant offset from the mean of a single fitted Gaussian model for each subject. Tissue-classified volumes were used to measure total cerebellar grey- and white-matter volumes.

For the regional assessment of grey matter in native space, the proportion of cerebellar voxels labelled as grey matter was calculated within volume-dependent spherical kernels with centres corresponding to the vertices of the subject's deformed cerebellar cortex model. These spherical kernels, with radius 15 mm, were varied subject-wise by the ratio of the individual to the average cerebellar volume, with the average determined from a reference sample (Rasser *et al.* 2010) of 18 control subjects also belonging to this study.

A deformable cerebellar atlas (Fig. 1b) (Rasser *et al.* 2010) was then deformed using cortical pattern-matching to the average target atlas, enabling the tabulation of each subject's average proportion of grey matter for each lobule. The deformable atlas was generated from a symmetrical version (across the central sagittal plane) of the Montreal Neurological Institute intensity-averaged single-subject MRI (Holmes *et al.* 1998). Labelling of lobule and feature boundaries of the deformable atlas was as described in Schmahmann *et al.* (2000).

Statistical analyses

Demographic data were compared between groups by non-parametric testing (i.e. χ^2 statistics with Yates correction when indicated) for nominal data or one-way ANOVA at $p < 0.05$ (two-sided). Data distribution was tested prior to parametric testing. Associations between parameters describing cannabis-use history (i.e. age of onset and duration of cannabis use and estimated individual total lifetime doses) were tested with Pearson's correlation coefficients at $p < 0.05$ (two-sided) in the cannabis-using group. Total cerebellar volume, total grey- and white-matter volumes, ratios of total grey:total cerebellar volumes, and lobule-level group differences of grey matter were tested by one-way ANOVA at $p < 0.05$ (two-sided and Bonferroni-corrected for multiple comparisons) between all four groups (i.e. non-using healthy control subjects, cannabis-using subjects, FES subjects, cannabis-using FES subjects). This was followed by Scheffé's *post-hoc* group comparisons and linear regression with the parameters describing cannabis-use history as predictors and lobule-level grey-matter differences as the dependent variable. The respective main effects and interaction between diagnosis of FES and cannabis use was tested by two-way ANOVA at $p < 0.05$ (two-sided) across all four groups.

Parametric statistical maps of cerebellar grey-matter measures by group (i.e. non-using healthy control subjects, cannabis-using subjects, FES subjects, cannabis-using FES subjects) were calculated and permutation-tested (Thompson *et al.* 2003) at $p < 0.05$ for each hemisphere. Permutation testing ascribes an overall corrected p value to a whole map of statistics, based on estimating the chance that the overall surface area of suprathreshold statistics could have been obtained by chance in null data, simulated by randomly assigning patients and controls to two groups.

Results

There was mixed support for the hypotheses. Cannabis use did not affect total cerebellar volume, white- or grey-matter volumes, nor total grey:total cerebellar volume ratios (Table 2). Parametric mapping suggested some regional effects of cannabis use on grey matter depending on age at onset of use, years of use, and accumulated total lifetime doses (Fig. 1c–e). Permutation testing confirmed significant grey-matter reduction for total lifetime dose for the right cerebellar hemisphere ($p = 0.04$, Fig. 1e).

The parameters describing cannabis use were partially inter-correlated in the otherwise healthy cannabis-using group. Age at onset of cannabis use

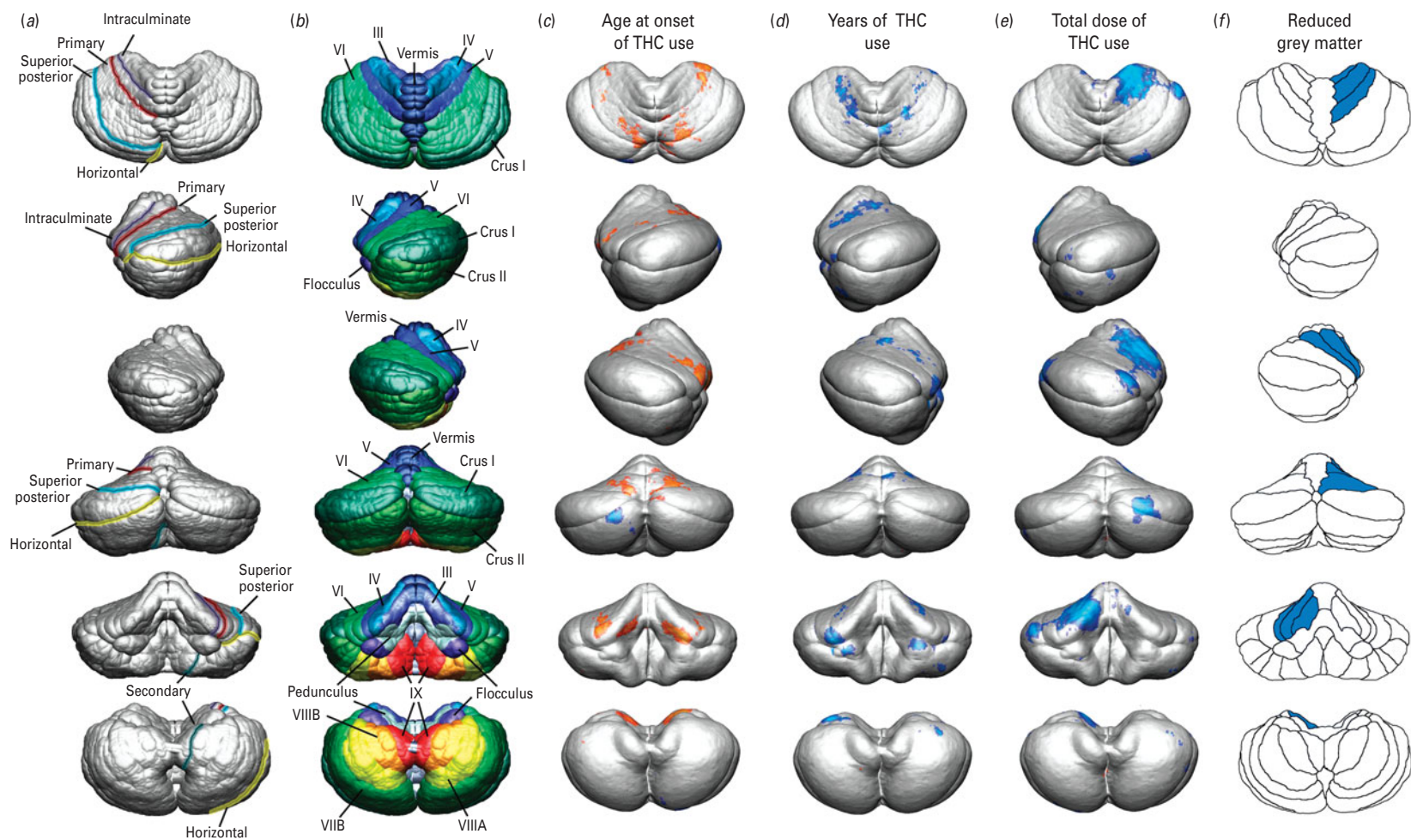


Fig. 1. From top to bottom, superior, left, right, posterior, anterior, and inferior views of cerebellum. (a) Traced fissure lines (intra-culminate, primary, superior posterior, horizontal, secondary) for cortex model transformation (modified from Rasser *et al.* 2010). (b) Deformable lobule labels, enabling lobule-wise grey-matter measures for each subject (modified from Rasser *et al.* 2010). Correlation maps of cerebellar grey matter with (c) age of onset of cannabis (THC) use, (d) years of use, and (e) cumulated lifetime exposure. (f) Cannabis-use history effects of juvenile THC use were statistically confirmed for the right lobules III, IV, and V.

Table 2. Comparisons of total cerebellar volumes, total grey- and white-matter volumes, and grey : total cerebellar volume ratios (standard deviations given in parentheses) for healthy control subjects, cannabis-using subjects, first-episode schizophrenia (FES) subjects, and cannabis-using FES subjects

	Control subjects (<i>n</i> = 19)	Cannabis-using subjects (<i>n</i> = 17)	FES (<i>n</i> = 13)	Cannabis using FES (<i>n</i> = 6)	<i>F</i> (d.f. = 3,54)	<i>p</i>
Total cerebellar volume (cc)	142.2 (13.1)	152.2 (13.9)	149.5 (10.5)	145.1 (7.4)	2.2	0.10
Total grey-matter volume (cc)	102.2 (10.0)	108.7 (9.7)	105.0 (7.3)	102.4 (5.4)	1.7	0.17
Total white-matter volume (cc)	40.0 (3.7)	43.5 (4.5)	44.4 (4.3)	42.7 (2.4)	3.8	<0.02*
Total grey : total cerebellar volume ratio	0.72 (0.01)	0.71 (0.01)	0.70 (0.02)	0.71 (0.01)	4.7	<0.01*

* Scheffé's *post-hoc* testing confirms increased total white-matter volume ($p=0.03$) and decreased total grey : total cerebellar volume ratio ($p=0.007$) in FES without cannabis use *vs.* control subjects.

correlated with years of use ($r = -0.52, p = 0.03$) which, in turn, correlated with total individual lifetime doses ($r = 0.58, p = 0.01$). Hence, *post-hoc* statistical analyses at lobule level were performed by linear regression with age of onset, years of use, and total lifetime doses as predictors and grey-matter measures in individual cerebellar lobules and areas as defined by Schmahmann *et al.* (2000) as the dependent variable. Consistent with parametric mapping (Fig. 1*c–e*), grey-matter reduction was confirmed for three lobules as dependent on the three parameters describing the pattern of cannabis-use history (lobule III: $F_{3,16} = 4.4, p = 0.02$; lobule IV: $F_{3,16} = 4.7, p = 0.02$; lobule V: $F_{3,16} = 4.6, p = 0.02$; Fig. 1*f*) with total lifetime doses significantly predicting grey-matter reduction in these lobules (lobule III: $\beta = -0.63, t = -2.6, p = 0.02$; lobule IV: $\beta = -0.74, t = -3.1, p < 0.01$; lobule V: $\beta = -0.52, t = -2.2, p < 0.05$; Supplementary Fig. S1, available online). Age at onset of cannabis use also showed a statistically non-significant trend towards being associated with grey-matter reduction in lobule III ($\beta = -0.46, t = -2.0, p < 0.07$; Supplementary Fig. S2, available online).

Parametric mapping suggested no regional differences in cerebellar grey matter in cannabis users *vs.* pair-wise age-, gender-, and handedness-matched healthy control subjects (Fig. 2*a*). By contrast, FES subjects showed a marked reduction of grey matter in the superior vermis, in left lobule VI, in right-inferior lobule IX, extending into left lobule IX, bilaterally in the areas of lobuli III, peduncle and left flocculus, compared to pair-wise age-, gender-, and handedness-matched healthy controls (Fig. 2*b*). These grey-matter deficits were confirmed by permutation testing for the left ($p < 0.003$) and right ($p < 0.005$) cerebellar hemispheres.

Grey-matter reductions in FES were also confirmed by parametric mapping across the three groups

(i.e. healthy control, cannabis user, FES subjects) by permutation testing for the left ($p < 0.002$) and right ($p < 0.003$) cerebellar hemispheres (Fig. 2*c*). Moreover, FES subjects also showed greater total white-matter volume ($p = 0.03$) and lower total grey : total cerebellar volume ratio ($p = 0.007$) than healthy controls (Table 2).

To assess the respective contributions of cannabis use and schizophrenia to regional grey-matter changes, all study participants were entered into a two-way ANOVA with the independent factors of cannabis use (yes/no) and the diagnosis of schizophrenia (yes/no). A main effect of the diagnosis of schizophrenia was confirmed for total grey : total cerebellar volume ratios ($F_{1,51} = 10.6, p = 0.002$; Supplementary Fig. S3, available online) due to grey-matter loss on lobules III, IV, V, VI, IX, pedunculi, flocculi, and vermis ($F_{1,51} = 4.5–14.3, p < 0.05–< 0.001$; Fig. 2*d* – light blue areas) which corresponds to the main effect of group in lobules III, IX, pedunculi, flocculi, and vermis ($F_{3,51} = 2.8–5.8, p < 0.05–0.002$; Fig. 2*d* – dark blue areas). After correcting for multiple testing (Bonferroni), smaller grey matter was confirmed in FES subjects without cannabis use *vs.* healthy control subjects, in the pedunculi, right vermis, left flocculus and right lobule III (Table 3). There was neither an effect of cannabis use ($F_{1,51} = 0.02$) nor an interaction of cannabis use with the diagnosis of schizophrenia on regional grey-matter differences in the cerebellum ($F_{1,51} = 0.84$).

Discussion

To our knowledge, this is the first study to link cerebellar pathology to juvenile cannabis use by employing cortical pattern matching. We found small dose-dependent regional effects of cannabis use in the cerebellum, resulting in reduced grey matter in the right lobules III, IV, and V that also tends to be more

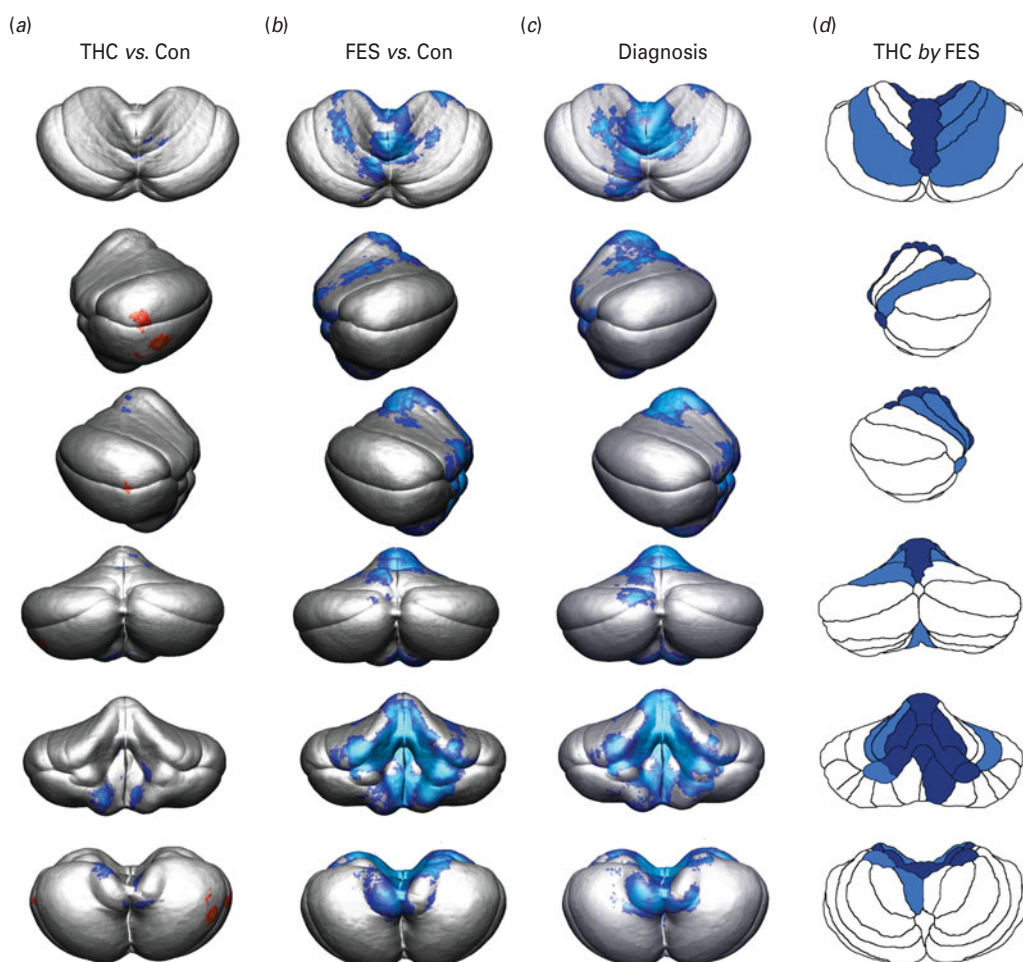


Fig. 2. From top to bottom, superior, left, right, posterior, anterior, and inferior views of cerebellum. (a) Parametric mapping suggests no regional differences of cerebellar grey matter in cannabis users (THC) *vs.* pair-wise age-, gender-, and handedness-matched healthy control subjects (Con). (b) By contrast, first-episode schizophrenia (FES) subjects present with marked reduction of grey matter in superior vermis; in left lobule VI, in right-inferior lobule IX, extending into left lobule IX, bilaterally in the areas of lobuli III, peduncle and left flocculus compared to pair-wise age-, gender-, and handedness-matched healthy control subjects (Con) (modified from Rasser *et al.* 2010). (c) A main effect of the diagnosis of schizophrenia was confirmed (d) due to grey-matter loss on lobules III, IV, V, VI, IX, pedunculi, flocculi, and vermis (light blue areas) which corresponds to the main effect of diagnosis of FES (two-way ANOVA of THC use by diagnosis of schizophrenia) in lobules III, IX, pedunculi, flocculi, and vermis (dark blue areas).

profound in lobule III with an earlier onset age of cannabis use. Despite dose-dependent regional grey-matter reduction in cannabis users, overall grey-matter measures were within the normal range of grey-matter variability for healthy subjects. By contrast, Medina *et al.* (2010) reported larger inferior posterior vermis volumes in recently abstinent cannabis users compared to a closely matched non-cannabis-using cohort. Their volumetric approach, however, does not discriminate between grey and white matter, nor does it adjust for individual lobular morphology when calculating group averages, thereby limiting the

comparability with the cortical pattern averaging method of the current study. On the other hand, remitted FES patients in the current study showed profound regional grey-matter reduction in the vermis, pedunculi, and right lobule III at an early stage of illness. The cerebellum was not atrophic in FES, in terms of overall volume, but patients had greater total white-matter volumes, resulting in smaller grey:total cerebellar volume ratios suggestive of impaired brain development (Harris *et al.* 1994).

Our findings confirm cerebellar grey- and white-matter pathology in schizophrenia (Andreasen &

Table 3. Comparison of grey-matter proportion by lobule (standard deviations given in parentheses) in the (a) left and (b) right cerebellar hemispheres for healthy control subjects, cannabis-using subjects, first-episode schizophrenia (FES) subjects, and cannabis-using FES subjects

Lobules	Control subjects (n=19)	Cannabis-using subjects (n=17)	FES subjects (n=13)	Cannabis-using FES subjects (n=6)	F (d.f. = 3,54)	p
(a) Left hemisphere						
III	0.72 (0.04)	0.71 (0.04)	0.69 (0.04)	0.71 (0.02)	2.8	<0.05
IV	0.78 (0.04)	0.78 (0.04)	0.75 (0.04)	0.77 (0.03)	1.6	0.19
V	0.75 (0.03)	0.74 (0.03)	0.72 (0.03)	0.74 (0.03)	2.2	0.10
VI	0.75 (0.02)	0.75 (0.03)	0.73 (0.02)	0.74 (0.03)	2.3	0.09
Pedunculus	0.64 (0.03)	0.64 (0.03)	0.60 (0.02)	0.63 (0.03)	5.4	<0.01*
Crus I	0.79 (0.02)	0.79 (0.02)	0.78 (0.03)	0.78 (0.02)	0.5	0.68
Crus II	0.76 (0.02)	0.77 (0.02)	0.76 (0.02)	0.76 (0.01)	0.3	0.82
VIIIB	0.76 (0.02)	0.76 (0.02)	0.75 (0.03)	0.76 (0.01)	0.2	0.91
VIIIA	0.76 (0.02)	0.76 (0.03)	0.75 (0.04)	0.76 (0.01)	0.4	0.73
VIIIB	0.77 (0.02)	0.77 (0.03)	0.75 (0.04)	0.76 (0.02)	1.0	0.40
IX	0.78 (0.02)	0.76 (0.03)	0.76 (0.03)	0.76 (0.04)	3.0	0.04
Vermis	0.80 (0.03)	0.78 (0.03)	0.76 (0.03)	0.77 (0.03)	3.2	0.03
Flocculus	0.66 (0.03)	0.66 (0.04)	0.63 (0.03)	0.63 (0.05)	3.3	0.03*
(b) Right hemisphere						
III	0.73 (0.04)	0.72 (0.04)	0.69 (0.03)	0.69 (0.03)	4.4	<0.01*
IV	0.78 (0.03)	0.78 (0.04)	0.76 (0.03)	0.74 (0.04)	2.2	0.10
V	0.75 (0.03)	0.75 (0.03)	0.72 (0.03)	0.74 (0.03)	2.6	0.05
VI	0.75 (0.03)	0.75 (0.03)	0.73 (0.02)	0.73 (0.02)	2.0	0.13
Pedunculus	0.65 (0.03)	0.64 (0.04)	0.61 (0.02)	0.61 (0.03)	5.8	<0.01*
Crus I	0.79 (0.02)	0.79 (0.02)	0.79 (0.03)	0.77 (0.00)	0.8	0.49
Crus II	0.77 (0.02)	0.77 (0.01)	0.77 (0.02)	0.76 (0.01)	0.7	0.54
VIIIB	0.76 (0.03)	0.76 (0.02)	0.75 (0.03)	0.75 (0.02)	0.2	0.92
VIIIA	0.77 (0.03)	0.77 (0.02)	0.76 (0.04)	0.78 (0.02)	0.9	0.44
VIIIB	0.78 (0.02)	0.77 (0.02)	0.76 (0.03)	0.78 (0.03)	1.6	0.20
IX	0.80 (0.02)	0.79 (0.02)	0.78 (0.03)	0.79 (0.01)	2.8	0.50
Vermis	0.80 (0.03)	0.79 (0.03)	0.77 (0.03)	0.77 (0.03)	3.9	0.01*
Flocculus	0.64 (0.03)	0.64 (0.03)	0.62 (0.02)	0.62 (0.06)	2.8	0.05

* Bonferroni-corrected *p* value. Scheffé's *post-hoc* testing confirms smaller grey-matter proportions in FES without cannabis use *vs.* healthy control subjects in left ($p=0.008$) and right ($p=0.02$) pedunculus, left ($p=0.04$) and right ($p=0.03$) vermis, and right lobule III ($p=0.02$).

Pierson, 2008; Picard *et al.* 2008). Moreover, these deficits are already detectable in the first-episode phase of the illness, following remission from acute psychosis. These findings are also consistent with findings from previous studies showing that the cerebellum contributes to the clinical, cognitive, and pathophysiological signs of the disorder.

For instance, vermal neuropathology has been reported previously and also appears to be present in neuroleptic-naïve schizophrenia patients (Ichimiya *et al.* 2001; Okugawa *et al.* 2007). Functionally, the vermis is mainly involved in spinocerebellar processing of axial muscle coordination but has also been

linked to impaired attention control, dysregulation of affect, social dysfunction and delusions (Schmahmann *et al.* 2008). This spectrum of psychopathology is consistent with some of the positive (e.g. delusions, inattention) and negative symptoms (e.g. flat affect, social withdrawal) of schizophrenia. Other reports found correlations of reduced vermal volume with the depression and paranoia subscores of the Brief Psychiatric Rating Scale (Ichimiya *et al.* 2001) and greater vermis white-matter volumes with severity of positive symptoms, thought disorder and impaired verbal logical memory in patients with schizophrenia (Levitt *et al.* 1999).

Neuropathology of the cerebellar pedunculi is also relevant to functional deficits described in schizophrenia, such as associative learning and the formation of memory traces for the conditioned eye-blink response (Thompson *et al.* 1997). Lower rates of eye-blink conditioning, particularly less adaptively timed conditioned response latencies, have been reported in schizophrenia (Bolbecker *et al.* 2009). Our finding of reduced grey matter in vermis and pedunculi suggests cerebellar pathology that is already emerging following the first episode of illness.

There seems to be some overlap in regional grey-matter pathology with cannabis use and FES in right lobule III, but there was no confirmation at group level owing to the overall small effects of cannabis use on grey-matter pathology. This observation is consistent with previous reports (Martín-Santos *et al.* 2010) and is supported by our data from cannabis-using FES subjects who do not show evidence of more profound cerebellar neuropathology related to their cannabis use. However, this observation must be regarded as preliminary owing to the small sample size of cannabis-using FES patients in our study.

On the other hand, according to a recent meta-analysis (Stoodley & Schmahmann, 2009), subtle grey-matter deficits in right lobules III, IV, and V in cannabis users may lead to somatosensory, language, verbal working memory, spatial, and executive function deficits and may also affect processing of emotional information. Our findings of greater cerebellar pathology with severity of cannabis-use history suggest more pronounced deficits in these functional domains with an earlier onset of use and more accumulated drug exposure. This interpretation is supported by meta-analytical data from a small number of studies of cannabis users by Grant and colleagues (2003). Cognitive deficits are most likely to occur in the domains of learning and memory, processing speed, and selective attention (see also reviews by Cohen *et al.* 2008; Solowij & Battisti, 2008). The potential impact on cognition of cannabis use requires further investigation.

Overall, our study is limited by sample size. This reflects our difficulties of recruiting non-drug-using FES patients and age-matched cannabis-using volunteers with no or very little abuse of other illicit drugs or alcohol. Recruitment of solely cannabis-using FES patients is most difficult owing to the high levels of multiple substance abuse in this population. On the other hand, our data suggest that cortical pattern matching overcomes some limitations of other morphometric methods by accurately aligning group-averaged cortical MRI data in relatively small cohorts,

thus providing the basis to map more accurately potential brain functional deficits onto *in-vivo* atlases of brain pathology.

Note

Supplementary material accompanies this paper on the Journal's website (<http://journals.cambridge.org/pnp>).

Acknowledgements

The study was supported by project grants of the National Health & Medical Research Council of Australia (300734), Pfizer Neuroscience, the Hunter Medical Research Institute, and the University of Newcastle. We gratefully acknowledge infrastructure support from the Hunter Medical Research Institute, the Schizophrenia Research Institute, and New South Wales Health and valuable assistance by V. Case, G. Cooper, D. Draganic, R. Fulham, S. Hudson, G. O'Connor. Algorithm development for this study was also funded by agencies of the U.S. National Institutes of Health: NIBIB (R01 EB007813, R01 EB008281, R01 EB008432), NICHD (R01 HD050735), and NIA (R01 AG020098).

Statement of Interest

None.

References

- Andreasen NC, Pierson R (2008). The role of the cerebellum in schizophrenia. *Biological Psychiatry* **64**, 81–88.
- Atkins M, Mackiewicz B (1998). Fully automatic segmentation of the brain in MRI. *IEEE Transactions on Medical Imaging* **17**, 98–107.
- Australian Institute of Health and Welfare (2008). Australia's Health 2008. Australian Institute of Health and Welfare, Canberra, Australia (<http://www.aihw.gov.au/publications/aus/ah08/ah08.pdf>).
- Bangalore SS, Prasad KM, Montrose DM, Goradia DD, *et al.* (2008). Cannabis use and brain structural alterations in first episode schizophrenia – a region of interest, voxel based morphometric study. *Schizophrenia Research* **99**, 1–6.
- Bolbecker AR, Mehta CS, Edwards CR, Steinmetz JE, *et al.* (2009). Eye-blink conditioning deficits indicate temporal processing abnormalities in schizophrenia. *Schizophrenia Research* **111**, 182–191.
- Borgwardt SJ, McGuire PK, Aston J, Berger G, *et al.* (2007). Structural brain abnormalities in individuals with an at-risk mental state who later develop psychosis. *British Journal of Psychiatry* **191**, S69–S75.

- Borgwardt SJ, McGuire PK, Aston J, Gschwandtner U, et al.** (2008). Reductions in frontal, temporal and parietal volume associated with the onset of psychosis. *Schizophrenia Research* **106**, 108–114.
- Cohen M, Solowij N, Carr V** (2008). Cannabis, cannabinoids and schizophrenia: integration of the evidence. *Australian and New Zealand Journal of Psychiatry* **42**, 357–368.
- Copeland J, Swift W** (2009). Cannabis use disorder: epidemiology and management. *International Review of Psychiatry* **21**, 96–103.
- Darke S, Ward J, Hall W, Heather N, Wodak A** (1991). *The Opiate Treatment Index (OTI) Researcher's Manual*. National Drug and Alcohol Research Centre Technical Report Number 11, 1991. Sydney: National Drug and Alcohol Research Centre.
- First MB, Spitzer RL, Gibbon M, Williams JBW** (1997). *Structured Clinical Interview for DSM-IV Axis I Disorders (SCID-I), Clinician Version*. Arlington, VA: American Psychiatric Publishing Inc.
- Glass M, Dragunow M, Faull RL** (1997). Cannabinoid receptors in the human brain: a detailed anatomical and quantitative autoradiographic study in the fetal, neonatal and adult human brain. *Neuroscience* **77**, 299–318.
- Gogtay N, Thompson PM** (2010). Mapping Gray Matter Development: implications for typical development and vulnerability to psychopathology. *Brain and Cognition* **72**, 6.
- Grant I, Gonzalez R, Carey CL, Natarajan L, et al.** (2003). Non-acute (residual) neurocognitive effects of cannabis use: a meta-analytic study. *Journal of the International Neuropsychological Society* **9**, 679–689.
- Harkany T, Keimpema E, Barabás K, Mulder J** (2008). Endocannabinoid functions controlling neuronal specification during brain development. *Molecular and Cellular Endocrinology* **286**, S84–S90.
- Harris G, Schlaepfer T, Peng L, Lee S, et al.** (1994). Magnetic resonance imaging evaluation of the effects of ageing on grey-white ratio in the human brain. *Neuropathology and Applied Neurobiology* **20**, 290–293.
- Holmes CJ, Hoge R, Collins L, Woods R, et al.** (1998). Enhancement of MR images using registration for signal averaging. *Journal of Computer Assisted Tomography* **22**, 324–333.
- Ichimiya T, Okubo Y, Suhara T, Sudo Y** (2001). Reduced volume of the cerebellar vermis in neuroleptic-naive schizophrenia. *Biological Psychiatry* **49**, 20–27.
- Keller A, Castellanos FX, Vaituzis AC, Jeffries NO, et al.** (2003). Progressive loss of cerebellar volume in childhood-onset schizophrenia. *American Journal of Psychiatry* **160**, 128–133.
- Lappin J, Dazzan P, Morgan K, Morgan C, et al.** (2007). Duration of prodromal phase and severity of volumetric abnormalities in first-episode psychosis. *British Journal of Psychiatry* **191**, S123–S127.
- Levitt JJ, McCarley RW, Nestor PG, Petrescu C, et al.** (1999). Quantitative volumetric MRI study of the cerebellum and vermis in schizophrenia: clinical and cognitive correlates. *American Journal of Psychiatry* **156**, 1105–1107.
- MacDonald D, Avis D, Evans AC** (1994). Multiple surface identification and matching in magnetic resonance images. In: Robb RA (Ed.), *Visualisation in Biomedical Computing. Proceedings of SPIE 2359*, 160–169. (<http://adsabs.harvard.edu/abs/1994SPIE.2359.160M>). Accessed 30 July 2010.
- Martín-Santos R, Fagundo AB, Crippa JA, Atakan Z, et al.** (2010). Neuroimaging in cannabis use: a systematic review of the literature. *Psychological Medicine* **40**, 383–398.
- Mata I, Perez-Iglesias R, Roiz-Santiañez R, Tordesillas-Gutierrez D, et al.** (2010). Gyrfication brain abnormalities associated with adolescence and early-adulthood cannabis use. *Brain Research* **1317**, 297–304.
- Mazziotta J, Toga A, Evans A, Fox P, et al.** (2001). A probabilistic atlas and reference system for the human brain: International Consortium for Brain Mapping (ICBM). *Philosophical Transactions of the Royal Society Series B: Biological Sciences* **356**, 1293–1322.
- Medina KL, Nagel BJ, Tapert SF** (2010). Abnormal cerebellar morphometry in abstinent adolescent marijuana users. *Psychiatry Research* **182**, 152–159.
- Moore TH, Zammit S, Lingford-Hughes A, Barnes TR, et al.** (2007). Cannabis use and risk of psychotic or affective mental health outcomes: a systematic review. *Lancet* **370**, 319–328.
- Nelson HE, Willison J** (1991). *The Revised National Adult Reading Test – Test Manual*. Windsor, UK: NFER-Nelson.
- Okugawa G, Nobuhara K, Takase K, Kinoshita T** (2007). Cerebellar posterior superior vermis and cognitive cluster scores in drug-naive patients with first-episode schizophrenia. *Neuropsychobiology* **56**, 216–219.
- Oldfield RC** (1971). The assessment and analysis of handedness: the Edinburgh inventory. *Neuropsychologia* **9**, 97–113.
- Pantelis C, Velakoulis D, McGorry PD, Wodds SJ, et al.** (2003). Neuroanatomical abnormalities before and after onset of psychosis: a cross-sectional and longitudinal MRI comparison. *Lancet*, **361**, 281–288.
- Picard H, Amado I, Mouchet-Mages S, Olié J, et al.** (2008). The role of the cerebellum in schizophrenia: an update of clinical, cognitive, and functional evidences. *Schizophrenia Bulletin* **34**, 155–172.
- Rais M, Cahn W, Van Haren N, Schnack H, et al.** (2008). Excessive brain volume loss over time in cannabis-using first-episode schizophrenia patients. *American Journal of Psychiatry* **165**, 490–496.
- Rasser PE, Schall U, Peck G, Cohen M, et al.** (2010). Cerebellar grey matter deficits in first-episode schizophrenia mapped using cortical pattern matching. *Neuroimage* **53**, 1175–1180.
- Schmahmann JD, Doyon J, Toga AW, Petrides M, et al.** (2000). *MRI Atlas of the Human Cerebellum*. San Diego, USA: Academic Press.
- Schmahmann JD, Smith EE, Eichler FS, Filley CM** (2008). Cerebral white matter: neuroanatomy, clinical neurology,

- and neurobehavioral correlates. *Annals of the New York Academy of Sciences* **1142**, 266–309.
- Sled JG, Zijdenbos AP, Evans AC** (1998). A nonparametric method for automatic correction of intensity nonuniformity in MRI data. *IEEE Transactions on Medical Imaging* **17**, 87–97.
- Solowij N, Battisti R** (2008). The chronic effects of cannabis on memory in humans: a review. *Current Drug Abuse Reviews* **1**, 81–98.
- Stoodley CJ, Schmahmann JD** (2009). Functional topography in the human cerebellum: a meta-analysis. *Neuroimage* **44**, 489–501.
- Substance Abuse and Mental Health Services Administration** (2009). Results from the 2008 National Survey on Drug Use and Health: National Findings. Rockville, MD: Office of Applied Studies, NSDUH Series H-36, HHS Publication No. SMA 09-4434.
- Takahashi T, Wood SJ, Yung AR, Soulsby B, et al.** (2009). Progressive gray matter reduction of the superior temporal gyrus during transition to psychosis. *Archives of General Psychiatry* **66**, 366–376.
- Thomann PA, Roebel M, Dos Santos V, Bachmann S, et al.** (2009). Cerebellar substructures and neurological soft signs in first-episode schizophrenia. *Psychiatry Research: Neuroimaging* **173**, 83–87.
- Thompson PM, Hayashi KM, Sowell ER, Gogtay N, et al.** (2004). Mapping cortical change in Alzheimer's disease, brain development, and schizophrenia. *Neuroimage* **23** (Suppl. 1), S2–S18.
- Thompson PM, Hayashi KM, de Zubicaray G, Janke AL, et al.** (2003). Dynamics of gray matter loss in Alzheimer's disease. *Journal of Neuroscience* **23**, 994–1005.
- Thompson RF, Bao S, Chen L, Cipriano BD, et al.** (1997). Associative learning. *International Review of Neurobiology* **41**, 151–189.
- United Nations Office on Drugs and Crime** (2008). Annual Report 2008. (http://www.unodc.org/documents/about-unodc/AR08_WEB.pdf).
- Vicente J, Olszewski D, Matias J** (2008). Prevalence, patterns and trends of cannabis use among adults in Europe. In: *A Cannabis Reader: Global Issues and Local Experiences* (pp. 6–26). Lisbon: EMCDDA.
- Whitford TJ, Grieve SM, Farrow TFD, Gomes L, et al.** (2006). Progressive grey matter atrophy over the first 2–3 years of illness in first-episode schizophrenia: a tensor-based morphometry study. *Neuroimage* **32**, 511–519.
- Witthaus H, Kaufmann C, Bohner G, Ozgürdal S, et al.** (2009). Gray matter abnormalities in subjects at ultra-high risk for schizophrenia and first-episode schizophrenic patients compared to healthy controls. *Psychiatry Research* **173**, 163–169.
- Yucel M, Solowij N, Respondek C, Whittle S, et al.** (2008). Regional brain abnormalities associated with long-term heavy cannabis use. *Archives of General Psychiatry* **65**, 694–701.